



**PATIENT**

Reddington Makin

**SPECIES**

Canine

**BREED**

Portuguese Water Dog

**SEX**

Male Neutered

**AGE**

13 years

**WEIGHT**

68.6lbs

**INTERPRETED BY**

Maggie Machen  
Lamy, DVM  
DACVIM (Cardiology)

**IMAGING PERFORMED BY**

Pamela Harrigan,  
RDCS

**HOSPITAL NAME**

Wood River Animal  
Hospital

**REFERRING VET**

Dr. Serra

**INVOICE**

22510

**DATE**

2/11/22

**PRESENTING CLINICAL SIGNS**

History: Recheck echo. History chronic valvular disease - Stage B1. History ASGA. Also, recent bout vomiting bile, abdominal pain/restlessness. Abdominal palpation revealed caudal abdominal mass. BUN 46; ALP 328; CBD WNL. 3 view chest radiographs normal. Having bi-cavity ultrasound exams.

-Pertinent previous echo findings (3/1/21 MML): LA 31. cm; LA:Ao 1.2; LV 3.65 cm; mild LAE; mild MR; trace TR.

\*Preliminary AUS findings: Splenic mass.

**ELECTROCARDIOGRAPHIC FINDINGS** \*Note: Single lead ECGs are evaluated as a rhythm strip. Morphology/MEA cannot be definitively commented on.

A single lead ECG is available; 25mm/s, 10mm/mV. The average heart rate is 90bpm (range 55-107bpm). The rhythm is sinus in origin, with a p for every QRS complex and vice versa. P and QRS morphologies are positive. Isolated single ventricular ectopy throughout. The coupling interval is not premature and is more consistent with AIVR. No supraventricular premature beats, pauses or other dysrhythmias observed. ECG diagnosis: Normal sinus rhythm with idioventricular ectopy.

**ECHOCARDIOGRAM FINDINGS**

2D, m-mode, color flow and Doppler imaging is available.

**Left ventricle:** The LV diameter is mildly dilated with adequate myocardial function. LV wall thicknesses are normal.

**Left atrium:** The left atrium is mildly dilated.

**Mitral valve:** The mitral valve is mildly thickened with no prolapse into the left atrial lumen. Mild eccentric mitral regurgitation with a normal velocity.

**Aortic valve/aorta:** The aortic valve is normal in morphology and mobility. Normal aortic outflow velocity; laminar flow. No aortic insufficiency.

**Right ventricle:** Normal right ventricular diameter and morphology indicating no overt evidence of pulmonary arterial hypertension.

**Right atrium:** Normal RA dimension. No obvious intra or extra-atrial masses.

**Tricuspid valve:** The tricuspid valve appears normal with trace tricuspid regurgitation.

**Pulmonic valve/pulmonary artery:** The pulmonic valve is normal in morphology and mobility. No pulmonic insufficiency. Normal RVOT velocity; laminar flow.

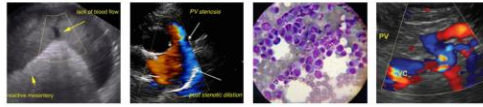
**Pericardium/other:** No pericardial or pleural effusion noted. No obvious cardiac masses.

**2-Dimensional Measurements**

Ao diam (cm)	2.8
LA diam (cm)	3.3
LA:Ao (Swe)	1.3
IVS thickness (cm)	1.0
LVID diastole (cm)	4.0
PW thickness (cm)	1.0
LVID systole (cm)	2.4
FS (%)	40

**Doppler Measurements**

PV Vmax (m/s)	0.5
AoV Vmax (m/s)	1.1
MR Vmax (m/s)	4.9
TR Vmax (m/s)	NA
TR PG (mmHg)	NA



**PATIENT**

Reddington Makin

**SPECIES**

Canine

**BREED**

Portuguese Water Dog

**SEX**

Male Neutered

**AGE**

13 years

**WEIGHT**

68.6lbs

**INTERPRETED BY**

Maggie Machen  
Lamy, DVM  
DACVIM (Cardiology)

**IMAGING PERFORMED BY**

Pamela Harrigan,  
RDCS

**HOSPITAL NAME**

Wood River Animal  
Hospital

**REFERRING VET**

Dr. Serra

**INVOICE**

22510

**DATE**

2/11/22

**INTERPRETATION OF THE FINDINGS**

Chronic degenerative valve disease persists without evidence of significant progression. Mild mitral and trace tricuspid regurgitation are unchanged with a stable left atrial dimension. The LV is slightly increased comparatively; however, no additional issues are identified. No obvious intra and extra-cardiac tumors are seen, as was noted on the previous study.

Continued assessment of progression in the future will help predict long term prognosis, which remains highly variable at this stage (B1).

The ECG does show isolated ventricular beats most consistent with an accelerated idioventricular rhythm (AIVR) based upon timing (lacking a tight premature coupling interval). No truly premature beats are seen (VPCs); however, this patient is at risk for development of true malignant ectopy given systemic illness.

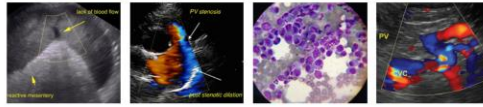
When sustained, AIVR is similar to VT in appearance as it is also generated from the ventricle; however, the rate is slower and there is typically no hemodynamic compromise (normal BP/pulses, no clinical signs). The term 'accelerated' is used as a comparison to the sinus rate (typically <180bpm). VT is a malignant, highly unstable rhythm with a HR>180-200bpm consistently and accompanies weakness, lethargy/collapse, poor peripheral pulses and hypotension. AIVR does not require therapy and does not generally lead to VT. AIVR typically develops due to extra-cardiac causes (such as adrenal/splenic tumors) and is likely related to splenic abnormalities. Simple monitoring is advised.

**RECOMMENDATIONS**

- No anti-arrhythmic or cardiac medications are advised at this time.
- Continued systemic screening (AUS, full lab work, CXR) highly recommended.
- Omega fatty acid supplementation and mild salt restriction may be of some long-term benefit.
- Anesthetic risk is considered mild if needed. Cardiac protective drug choices (opioid/benzodiazepine premedication, propofol or alfaxalone induction, isoflurane gas) are recommended. Pre-oxygenate for 5-10 minutes prior to induction. Monitor for arrhythmias, hypotension, and hypoxia both intra and post-operatively and intervene as necessary. Mild IV fluid restriction is recommended to avoid fluid overload. Avoid heart rate stimulating drugs such as atropine unless clinically indicated. **Monitoring of the ECG is advised both intra and post-operatively, paying close attention to the heart rate and systemic pressures with any sustained ventricular rhythms. Treatment with lidocaine is only advised if sustained VT is confirmed >180bpm.**
- Monitor for development of a cough, labored breathing, exercise intolerance or collapse episodes.

**PLAN**

- Recommend conservative monitoring with a recheck echocardiogram in 6-12 months, sooner if any development of clinical signs.



**PATIENT**

Reddington Makin

**SPECIES**

Canine

**BREED**

Portuguese Water Dog

**SEX**

Male Neutered

**AGE**

13 years

**WEIGHT**

68.6lbs

**INTERPRETED BY**

Maggie Machen  
 Lamy, DVM  
 DACVIM (Cardiology)

**IMAGING PERFORMED BY**

Pamela Harrigan,  
 RDCS

**HOSPITAL NAME**

Wood River Animal  
 Hospital

**REFERRING VET**

Dr. Serra

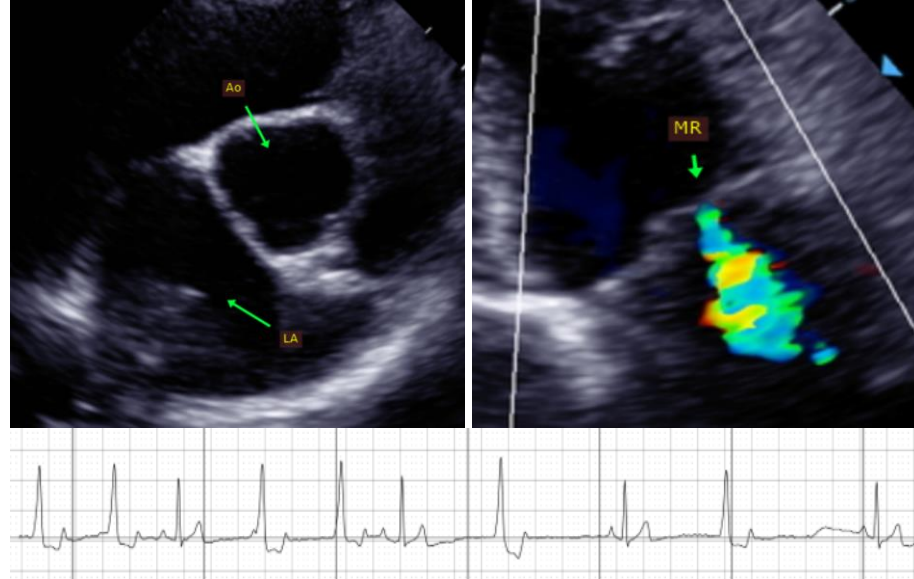
**INVOICE**

22510

**DATE**

2/11/22

**IMAGES**



The information and recommendations provided are based on the images presented by the referring veterinarian. No evaluation can be communicated regarding pathology that was not visible in the image/video clips provided.

Thank you for this referral. This report was generated using transcription software, and minor dictation errors may be present. If the clinical or image interpretation does not parallel your findings or if I can be of any further assistance, please contact me.

**Maggie Machen Lamy, DVM**  
 Diplomate of the American College of Veterinary Internal Medicine (Cardiology)  
 info@sonopath.com